

# Compressed Air Injury to the Colon/Rectum and its Sequelle

MANSAB ALI, HAMMAD RANA, FAIZUL HASAN, TAHIR CH, ATIF, SABIR

## ABSTRACT

Colonic injury due to pressurized air is a unique pathology which is now being reported increasingly with the extensive use of compressed air in this industrial era (1). We are reporting 10 cases of colorectal injures due to compressed air directed to the anus while playing practical jokes at work place. All the patients presented to the A/E with the sign and symptoms of peritonitis. They were diagnosed clinically and confirmed with the help of X. ray's and USG showing dilated colon and gas under the diaphragm. None of our patient had respiratory distress. After preoperative resuscitation, all patients underwent explorative laparotomy. Perforation was sutured and a proximal colostomy was made in the patient with multiple perforations. Patients with single perforation was brought out as colostomy. The colostomy was reversed after 6-8 weeks of surgery. All of them made uneventful recovery.

**Key words:** Pressurized air, Colonic ruptures and Colostomy.

## INTRODUCTION

In the era of industrialization compressed air is used in almost every industry i.e. plants, ship yards and manufacturing industries.

As the use of Compressed air in industries has increased, so has the risk of associated pneumatic injuries from its use while playing practical jokes. Colorectal injuries have always been a challenge for the surgeon. The reason is the high incidence of spillage of the gut contents into the peritoneum, resulting in development of peritonitis, septic complications and leads to high morbidity and mortality rate.

Compressed air injuries should be taken seriously because the high pressure of compressed air into the rectum in a very short time can overcome barriers as clothes and anal sphincter delivering enormous amount of pressurized air into the rectum, resulting in rectal and colonic perforation and development of tension pneumoperitoneum<sup>1</sup>.

Anatomy of rectum: Shorter and relatively stockier, the large intestine is a dark reddish color, measuring roughly 1.5 meters (5 ft) long on average. It is divided into five parts<sup>10</sup>, ascending colon, transverse colon descending colon, sigmoid colon, rectum

Department of Surgery, Social Security Hospital Lahore  
Address for correspondence: Dr Mansab Ali, Email: m.mansab@yahoo.com

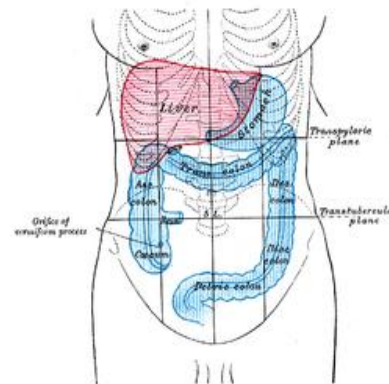
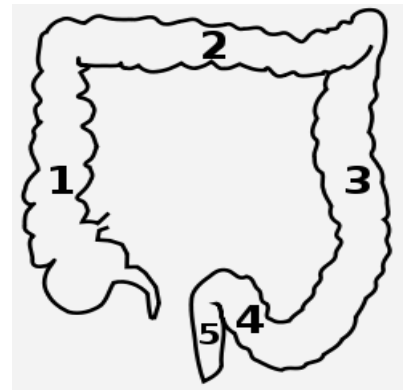


Figure  
1 Ascending colon, 2 Transverse colon, 3 Descending colon, 4 Sigmoid colon, 5 Rectum.  
Anatomical location in abdominal cavity

We have studied the clinical presentation, sites of perforation, management and surgical outcome of injuries due to compressed air in Social Security Hospital. This is a tertiary 620 beds teaching hospital, attached with UCMD and provides Emergency/Elective care to industrial workers referred from the industrial areas all around Punjab especially the city of Lahore. We present our experience of dealing with the patients with colorectal injuries.

**METHODS**

Prospective study was conducted at Nawaz Sharif Social Security Teaching Hospital from 2006-2008. This hospital deals with the population working in the industries. Age and sex of all patients were recorded. All patients presented with acute abdominal their sign and symptoms recorded. Tension pneumoperitoneum resulting from compressed air directed to the anus while playing practical jokes. Duration from the time of the infliction of the injury and presentation to A/E was also noted.

Following investigations were performed in every patients (CBC's, LFT's, RFT's, Serum electrolytes, Urine C/E, HBsAg, and Anti-HCV) and Radiological studies of chest and abdomen.

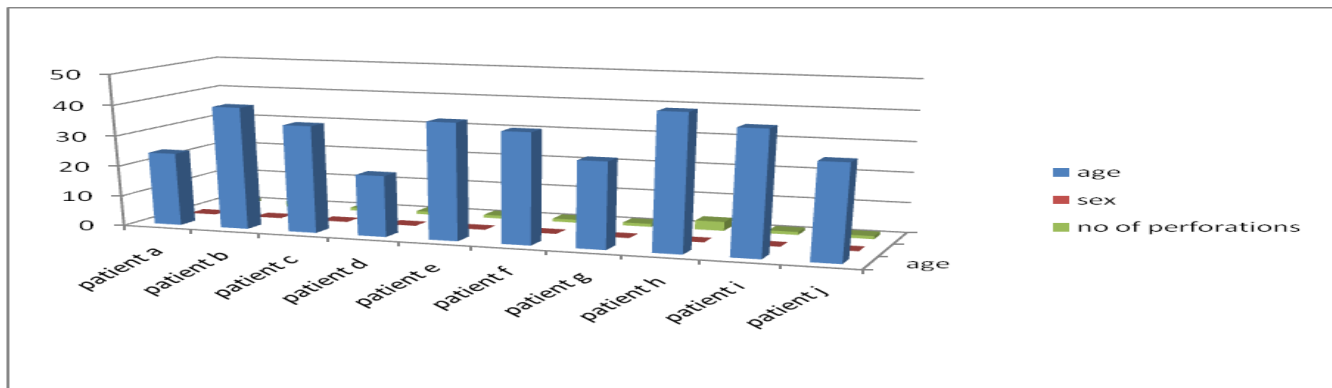
Patients were resuscitated in emergency with I/V fluids and NG tube and appropriate anti-biotic given. All patients underwent exploratory laparotomy.

Abdomen opened through a midline incision, site and size and no of perforation and other associated injuries noted. Abdomen washed with normal saline. Single perforation was brought as colostomy. In patients with multiple perforations distal perforation repaired and proximal colostomy made drain placed in pelvis, abdomen closed with mass closure. Drain removed at 3<sup>rd</sup> day. Complications noted during follow up at 4-6 weeks post operatively and then patients admitted 8-12 weeks for reversal of colostomy. Colostomy reversal done after barium enema and complications of colostomy reversal also noted.

**RESULTS**

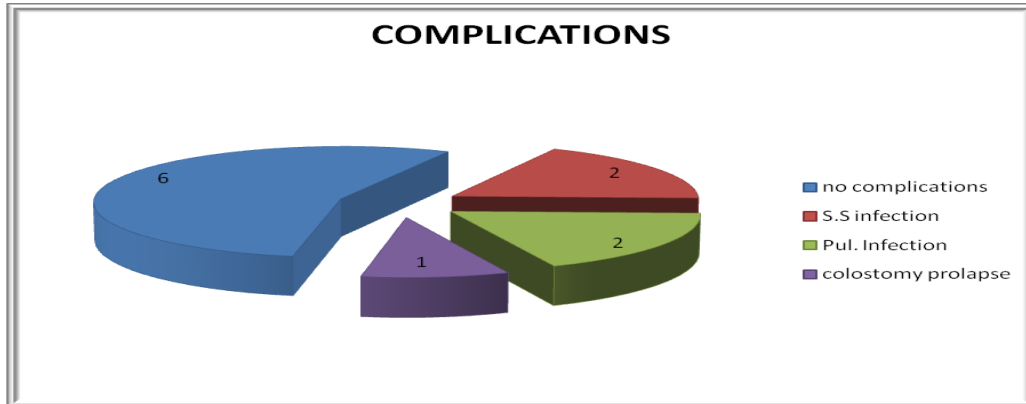
The study was carried out from 2006 to 2008. All our patients were males with age ranging between 20-45 years with median age of 32.5 years. Perforations occurred at the anterior wall of the rectum in 2 cases, sigmoid colon in 2 cases, recto sigmoid junction in 3 and 3 in the descending colon. In 8 cases there was a single perforation, 1 case had 2 perforations and 1 had 3 perforations. All patients presented within 6-24 hours of the injury. All our patient remained in hospital for a period of 8-10 days.

Patient name	Age	Sex	No of perforations	Site of perforations
Patient A	24	Male	1	Rectum
Patient B	40	Male	2	Recto sigmoid junction
Patient C	35	Male	1	Recto sigmoid junction
Patient D	20	Male	1	Rectum
Patient E	38	Male	1	Sigmoid colon
Patient F	36	Male	1	Sigmoid colon
Patient G	28	Male	1	Descending colon
Patient H	44	Male	3	Recto sigmoid junction
Patient I	40	Male	1	Descending colon
Patient J	31	Male	1	Descending colon



All patients were kept under observation and following complications were noticed during the Hospital follow up visits.

1. Surgical wound infections occurred in 2/10 (20%) cases.
2. Pulmonary complication i.e. Atelectasis/Pneumonia in 2/10 (20%).
3. Colostomy prolapsed occurred in 1/10 (10%) patient.
4. Complications of reversal of colostomy 2/10 (20%).
5. Mortality (all our patients survived).



## DISCUSSION

Pneumatic colonic injury has been reported sporadically since the first report by Stone in 1904<sup>2</sup> and reviewed in detail by Brown and Dwinelle<sup>3</sup> in 1942. An experimental study on the relationship between intestinal rupture and air pressure was performed by Burt<sup>4</sup> in 1931. According to this study of the four layers of the intestinal wall, the mucosa is the strongest layer and when pressure increases progressively the muscle and serosa tear first, then the mucosa. A pressure of 3.99 psi tears the muscle and serosal layer of intestine and 4.07 can rupture the whole intestinal wall leading to perforation. The usual pressure of compressed air is 50-150 psi which is 10-30 times greater than the pressure needed for intestinal perforation. The site of perforation with the compressed air is reviewed. The vast majority are in the recto sigmoid junction, minor is in the ascending colon, hepatic flexure and transverse colon. Injury to small intestine due to compressed air has not been reported. The anatomical configuration of the buttock and perineum is like a funnel; it allows easy delivery of compressed air in the anal orifice. Cloths do not alter the effect of compressed air. As the anal canal and descending rectum is well supported by outside structure. The antimesenteric border of the recto sigmoid is the first part of colon strike by column of air and is the most common site of perforation<sup>5</sup>.

Clinical manifestation depends upon the extent of intraluminal pressure leading to colonic perforation and causing tension pneumoperitoneum. Colonic perforation can occur at single or multiple sites<sup>3</sup>, abdominal pain and distension develops rapidly and if colon perforates, peritoneal irritational sign will also be present. Like other studies all our patients developed sign and symptoms of peritonitis, but none of them had tension pneumoperitoneum. Frequently sign of respiratory distress is seen because of pneumoperitoneum which reduces diaphragmatic movements. Hyperventilation develops resulting in mild to moderate respiratory alkalosis. Tension pneumoperitoneum compresses the vena cava decreasing venous return to heart, hypotension and circulatory collapse.

Paracentesis of the cavity with the needle or trocar is a simple and useful method and enough to reverse the respiratory distress<sup>7,8</sup>. After recovery from the initial shock, peritonitis due to fecal contents of the peritoneal cavity should be treated immediately.

With modern treatment, diffuse peritonitis carries mortality of about 10%<sup>9</sup>. But no mortality has been reported in our study. All our patients had developed fecal peritonitis and that was treated with appropriate anti biotic and peritoneal lavage and placement of a drain was done. Colostomy reversal was carried out 8-12 weeks after the operation and reversal went uneventful except 2 of them in which surgical scar infection occurred and treated with anti biotic.

The prognosis has generally been favorable in recent years, although early correction before 1950 where conservative management was employed reported grave consequences (mortality rate of 80-100%)<sup>3,4</sup>. As conclusion earliest possible exploration is mandatory.

## CONCLUSION

Colonic injury due to pressurized air is unique pathology which is now being reported increasingly with the extensive use of compressed air in this industrial era. This condition must be taken seriously because its results could be devastating. This must be considered as a differential diagnosis in patient with abdominal distention or peritonitis. Radiological studies helps in making the diagnosis and tension-pneumoperitoneum should be decompressed with use of a needle or a trocar. This is followed by explorative laparotomy bringing the only perforation as colostomy and repaired primarily with a covering colostomy in multiple perforations.

## REFERENCES

1. Yonsei Medical Journal. Vol 41, No. 4, pp 533-535, 2000.
2. Stone GW rupture o bowel caused by compressed air. Lancet 1904; 2:216.
3. Brown RK, Dwinelle JH. Rupture of the colon by compressed air. Ann. Surg. 1942; 115:13-20.
4. Burt CAV Pneumatic rupture of the intestinal canal with experimental data showing the mechanism of perforation and the pressure required Arch Surg. 1931; 22:875-902.
5. Andrew EW. Pneumatic rupture of intestine, a new type of industrial accident. Surg. Gynae/Obst. 1911; 12:63-72.
6. Sei Joong Kim. Pneumatic Colonic rupture accompanied by Tension Pneumoperitoneum. Yonsei Medical Journal 2000; 533-535.
7. Suh HH, Kim YJ, Kim SK. Colorectal injury by compressed air a report of 2 cases. J KOREAN Med Sci 1996; 11: 179-82.
8. Zechel GL. Pneumatic rupture of colon as an industrial injury. Industrial Med Surg 1967; 36:663-667.
9. Baileys and Love's (short practice of surgery edition 24<sup>th</sup>). Acute peritonitis. P. 1133
10. Wikipedia, the free encyclopedia